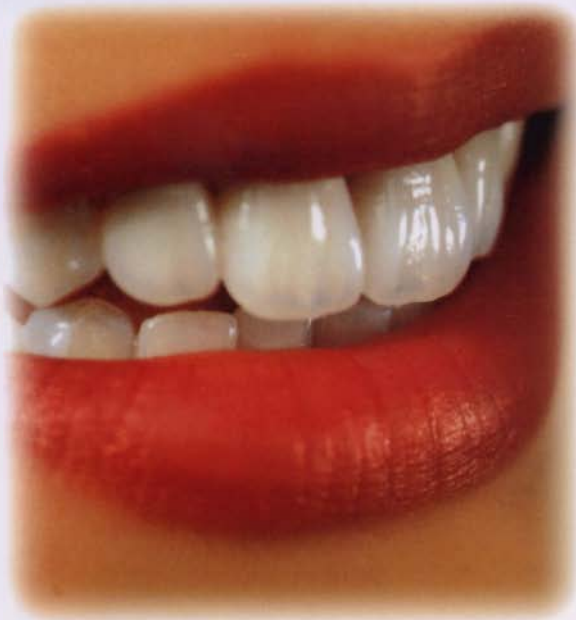



IPSEmpress®

The ultimate in metal-free esthetics.

Anterior Chairside Preparation Guide

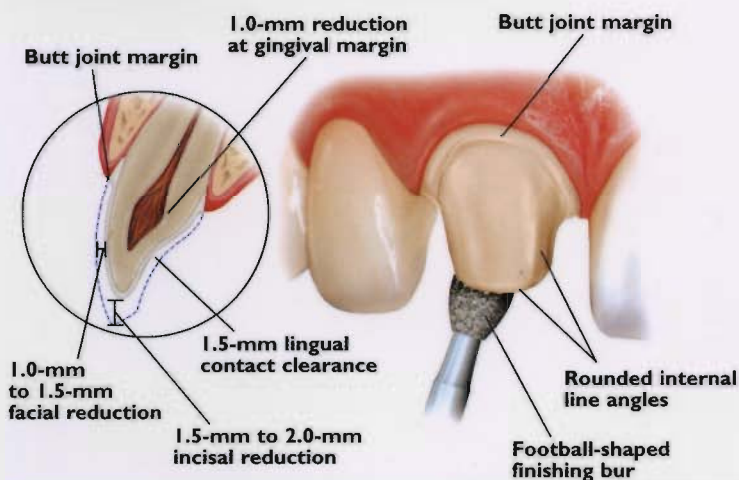
FOR IPS EMPRESS® AND IPS ERIS® RESTORATIONS

		IPS Empress	IPS Eris
Anterior	Crown	X	X
	Veneer	X	
	Bridge		X
Posterior	Crown	X	X
	Bridge		X [†]
	Inlay/Onlay	X	

[†]One pontic and the second premolar as the most distal abutment.

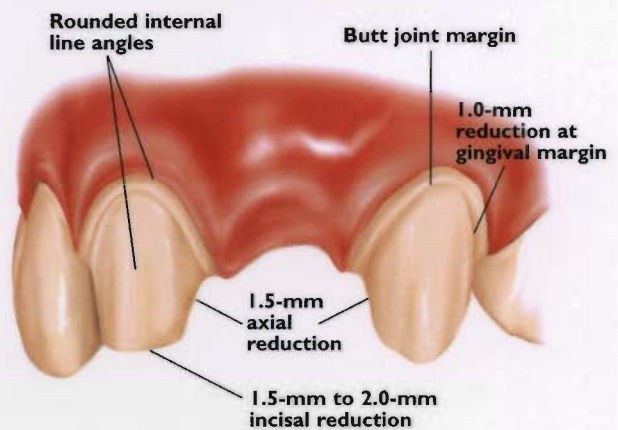
Full-Coverage Restorations

ANTERIOR CROWN PREPARATION



3-Unit Bridge Restorations

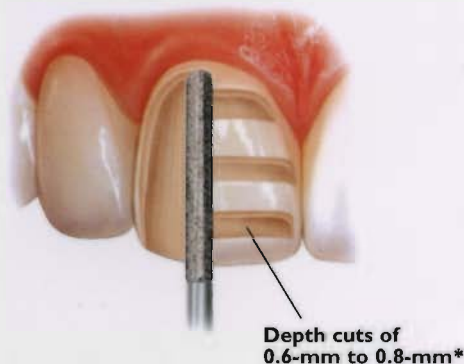
3-UNIT BRIDGE PREPARATION



Veneers (IPS Empress® Staining Technique)

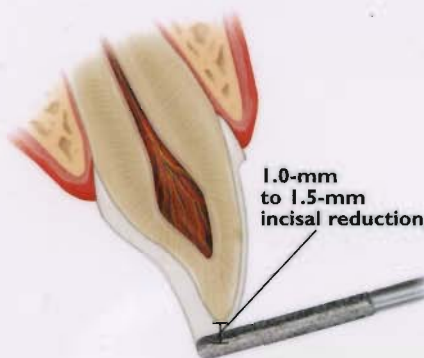
UNIFORM FACIAL PREPARATION

A medium grit, round-ended, diamond bur is used to remove a uniform thickness of facial enamel by joining the depth-cut grooves.



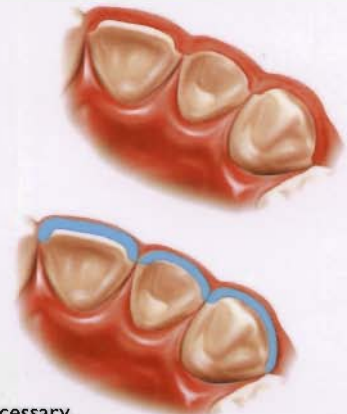
INCISAL PREPARATION

The diamond bur is angled to bevel back the incisal edge.



CHAMFER MARGINS

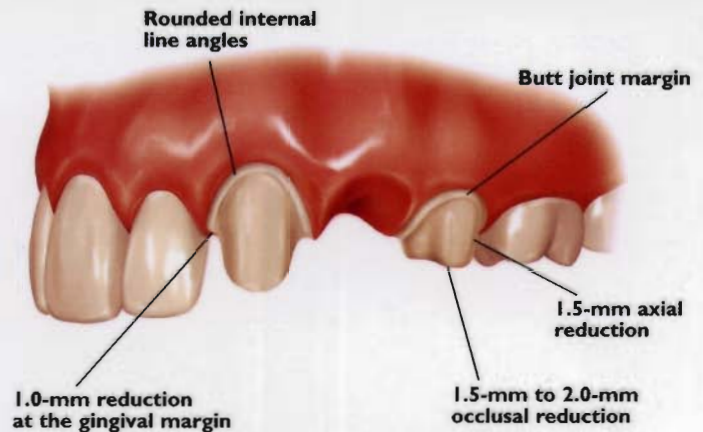
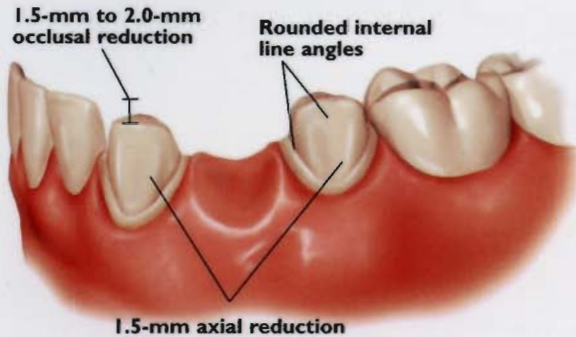
Correct preparation of the chamfer margins interproximally allows the appropriate bulk of porcelain.



*Please note: For additional masking capabilities and/or layering techniques, further reduction may be necessary. Contact your laboratory for further information.

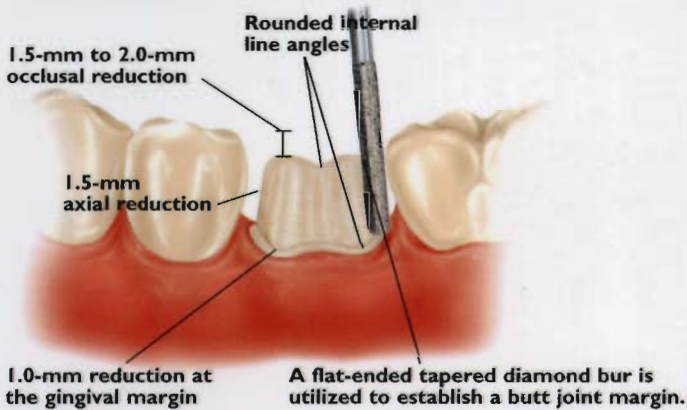
3-Unit Bridge Restorations

3-UNIT BRIDGE PREPARATION

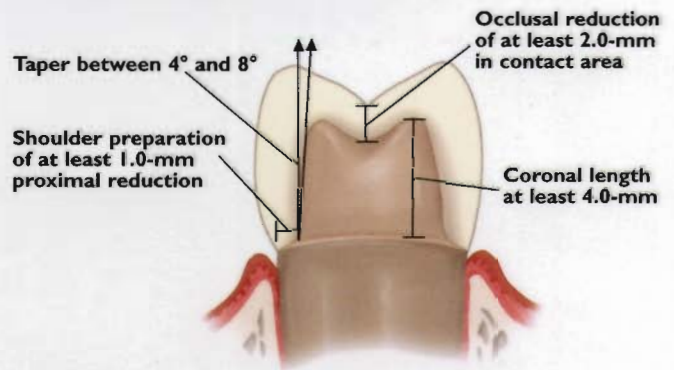


Full-Coverage Restorations

POSTERIOR CROWN PREPARATION

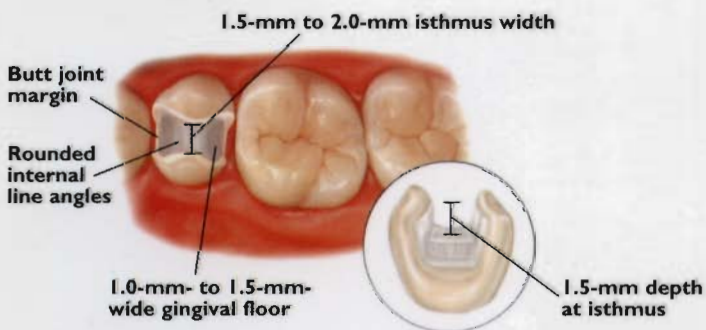


CONVENTIONAL CEMENTATION PREPARATION



Inlays/Onlays

INLAY PREPARATION



ONLAY PREPARATION

